

SAFETY AND EFFECTIVENESS OF RADIOFREQUENCY ABLATION OF GREATER SAPHENOUS VEIN: SINGLE CENTER EXPERIENCE

George Jinchveladze, Guram Vardishvili, Sandro Tsikarishvili

Caucasus Medical Center, Department of Vascular and Endovascular Surgery

Contact person: George Jinchveladze, gioangio1@yahoo.com

DOI: <https://doi.org/10.48412/GTBGS.2024.12.61-64>

Resiue Mission: find out the safety and effectiveness of radiofrequency ablation of greater saphenous vein during Chronic venous disease, Varicose Veins.
 Method: primary evaluation using DUS, VCSS score, and CEAP classification, evaluated a total of 220 patients during the 2017-2022 year, which came down to surgical treatment.
 Result: from these 220 patients median age was 46.6 years, male to female ratio was 77 % to 23%. The postoperative evaluation showed significant improvement in Quality of life and outcome of disease. The occlusion rate in our procedures was 98.8%, recanalization rate after 1 year of the procedure was 3.6%. Also, age >65 was an additional risk factor for hyperpigmentation, edema, and paresthesia.
 Conclusion: RFA of GSV has proved itself as a safe and effective method. More than 95% of patients are suitable for RFA during CVI in the lower extremities, in others open surgical operations are indicated. The main complication rate was low, with a recanalization rate of less than 4% and an occlusion rate of 98.8 %. Also, hospital delay was minimal and the return in normal function was on the second day after the procedure.

Key points: radiofrequency ablation of greater saphenous vein, complications, safety, effectiveness, single center experience

INTRODUCTION

Chronic Venous Disease (CVD) of lower extremities is seen widely in today's vascular surgeon's practice, CVD manifests itself in various clinical spectrums, ranging from asymptomatic but cosmetic problems to severe symptoms such as thrombophlebitis and ulcer. Varicose vein disease is the main reason of CVD in lower limbs. Pain, swelling, heaviness and tingling of the lower limbs are the most common and symptoms caused by varicose veins while in some individuals it is asymptomatic [1,3,5]. Risk factors associated with age, gender, occupation, pregnancy, family history, smoking and obesity. In the last two decades, modern technologies have stepped in surgical treatment of Varicose vein disease. Were developed two main thermal ablation methods: Radiofrequency ablation (RFA) and Laser Ablation (EVLA) that made huge impact on outcome of disease [2,3,9].

MATERIAL AND METHODS

As it was mentioned, in In presented study we collected data about complications after RFA of great saphenous vein (GSV) which was held in our center from 2017 to 2022 year. The main method for planning the intervention on superficial veins was duplex ultrasonography (DUS) of the veins of lower extremities, during which was done mapping of abnormal pathways, identification of sources of reflux, reflux site and length [1]. All patient were evaluated by using CEAP and VCSS classification tools. Indica-

tions for Treatment with superficial venous incompetence, management strategies mainly depended on clinical presentation (history, symptoms, signs) and detailed individual DUS findings, which were all mandatory for proper decision making, also reflux and occlusion in deep veins were excluded [7]. Treatment strategy was based on recommendation (ESVS 2022 Clinical Practice Guidelines on the Management of Chronic Venous Disease in Lower Limbs, recommendation №15, [1]) according which patients with superficial venous incompetence presenting with symptomatic varicos veins (VV) starting from CEAP C2s, superficial venous incompetence presenting with skin changes as a result of chronic venous disease (CEAP C4-C6), interventional treatment was recommended. Patients were also examined after one week post-operatively. Additionally,

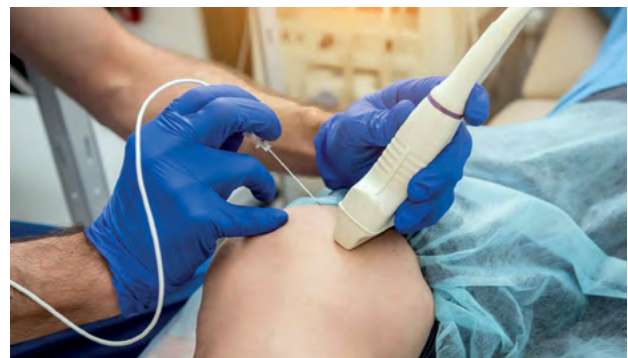

Figure 1. Radiofrequency ablation of the great saphenous vein using duplex ultrasound of the lower extremity veins.

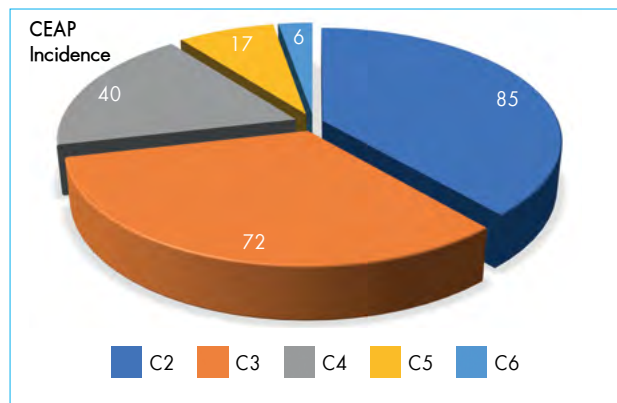
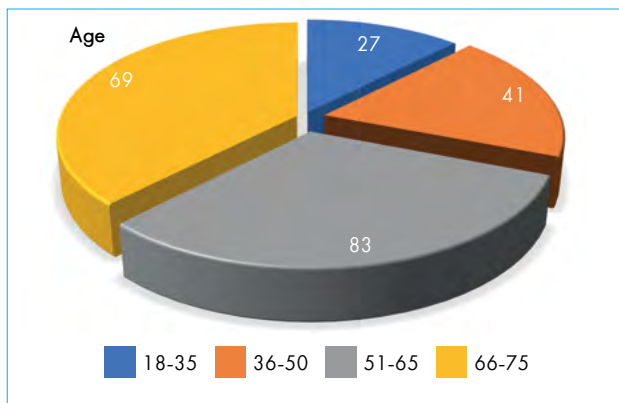


Figure 2. Distribution of patients according to Age and CEAP classification

DUS was performed after 12 month to detect possible recanalization. For RFA of GSV we used ClusureFast catheter (Medtronic Inc, USA) during surgery, constructed with bipolar electrode affixed to its distal end. The mechanism is such that electrode must make direct contact with vein wall to deliver radiofrequency energy, contact with wall results in destruction of endothelium, occlusion by contraction of vein wall collagen, and thrombus formation [2,6,8]. For ablation of GSV access was initiated at GSV's most distal site of reflux source, lidocaine was administered at the selected area and with the help of needle was punctured vein under ultrasound guidance. A 0.018 -inch guidewire was inserted into GSV, and the needle was removed. Next a 7F X 11 cm sheath was advanced OTW, the 0.018inch wire was removed, 7F RFA catheter was inserted until 2 cm peripheral to SFJ [2]. Peri-venous tumescent anesthesia was administered under ultrasound guidance along the entire treatment length [2,5]. RFA was performed and after catheter and 7f sheath was extracted. Tumescence reduces pain, induces venous compression and spasm leading to greater effectiveness, and acts as a heat sink to protect surrounding structures. [1] A standardized tumescence composition consisting of 445 ml crystalloid, 50ml 1% lidocaine plus 1:100 000 adrenaline and 5ml 8.4% sodium bicarbonate was used [1]. Recent ESVS 2022 Clinical practice Guidelines on the management of CVD of lower limbs have identified reduced pain when pH of acidic lidocaine solutions is neutralized by the addition of sodium bicarbonate, to create buffered solutions [2,7,8]. Addition of adrenaline prolongs the anesthetic effect and provides vasoconstrictive effect [1,2]. Preoperative planning consisted of examination and DUS, well hydration before procedure to achieve maximum distention of leg veins. [1] Compression therapy was used after procedure during 14 days to prevent or minimize inflammation, pain, bruising, bleeding, hematoma and superficial and deep vein thrombosis, compression of 35mmHg<P>40mmHg was used standardly. For patients with superficial venous incompetence undergoing ultrasound guided foam sclerotherapy or endovenous thermal ablation of a saphenous trunk, post-procedural compression treatment should be considered [1] For thromboprophylaxis single dose of low molecular heparin (LMWH) was used once a day from

4.000 IU to 6.000 IU [1,2]. (Recommendation №18, For patients with superficial venous incompetence, undergoing treatment using endovenous techniques with or without phlebectomies, the procedure should be performed in the outpatient setting where possible [1].)

RESULTS

We retrospectively analyzed the data of patients about RFA of greater saphenous vein (GSV), with or without phlebectomy, its safety, complications and effectiveness, surgical cases took place during 2017-2022 in 220 patients. A total of 220 patients underwent RFA of GSV. The mean age was 46.5 year, female to male population was 77% and 23%, respectively. Follow-up period was 12 month, the CEAP score, VCSS, and QoL score were significantly improved. The occlusion rate 98,8%. (GSV diameter >8mm). Clinically patient's conditions were evaluated using CEAP Classification, in this article range of our patients were from C2 to C6 (C2 class -39%, C3 class -33%, C4 class -18%, C5 class -8%, C6 class -3%). Additional VCSS classification was use during complicated cases. Inclusion criteria for procedure also was diameter of GSV from 4-15mm. Notably in our cases hematoma only occurred when patients had undergone RFA with phlebectomy. In all of our cases, besides it was with or without phlebectomy, Tumescent anesthesia was performed under ultrasound guidance. It allowed early return to normal function and significant improvements in quality of life. This provides efficient treatment, with minimal discomfort, time in hospital delay in our cases were from 16-24 hours [1]

In our study we encountered incidence of CEAP classified patients. Complications during surgery was defined: Vessel perforation (0), Pulmonary Embolism (PE) (0), DVT (2), Phlebitis (9) , infection (17).

Complications after procedure consisted of: Ecchymosis (8 3,6%), hyperpigmentation (2,7%), hematoma (17, 7.7%) , erythema (14 6.3%), phlebitis (3, 1.3%), DVT (0), PE (0). Additionally, we evaluated recanalization rate after 1 year of procedure, only in 8 patients (3.6%) after 1 year we found recanalization. [1,2,5,7,9]

As we mentioned upward, in complicated cases we use additional VCSS classification for evaluation and determi-

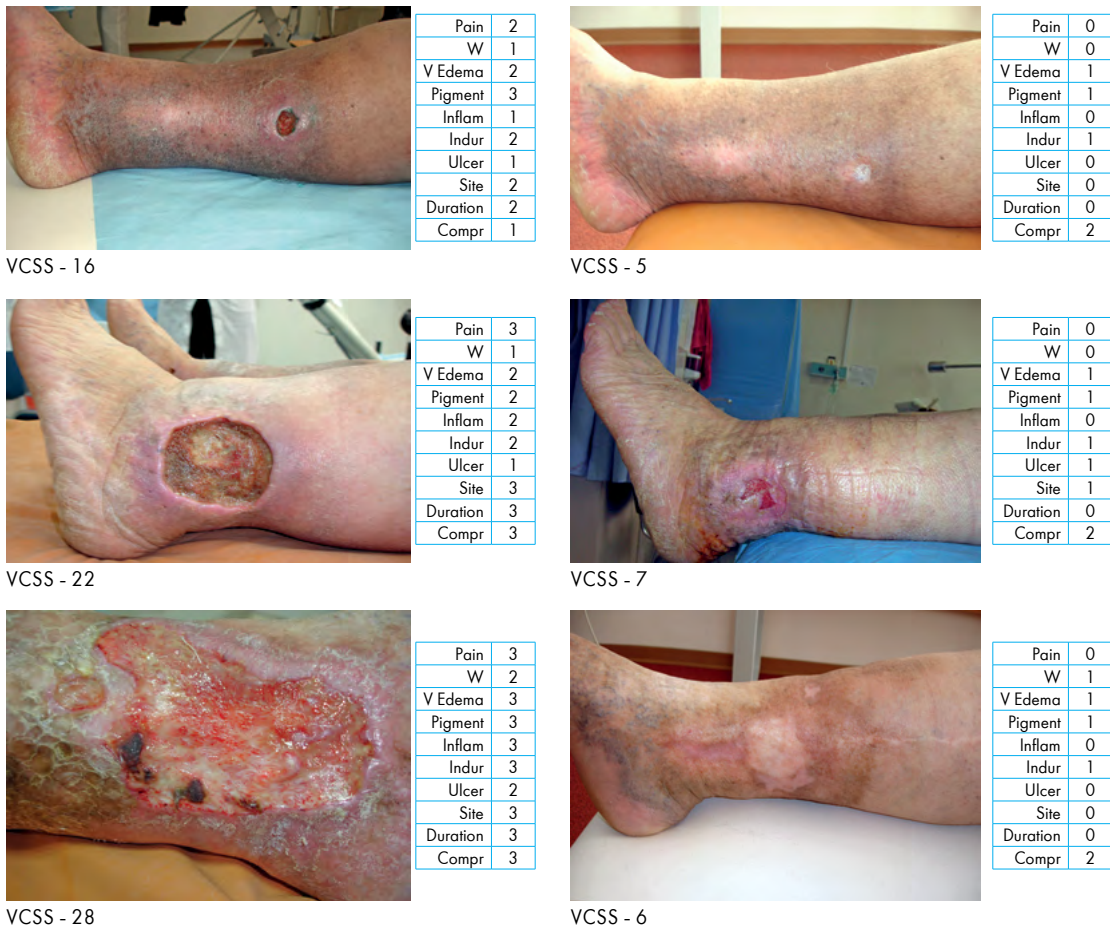

Figure 3. Evaluation of treatment effectiveness by VCSS classification; Our clinical cases, dynamics of complications on the lower limbs

nation of treatment effectiveness. We will provide below some of our examples.

From this experience we saw significant improvement QoL [1] in small amount of time with the help of procedure and recommendations during and after the surgery for our patients.

ლიტერატურა:

References:

1. European Society for Vascular Surgery (ESVS) 2022 Clinical Practice Guidelines on the Management of Chronic Venous Disease of the Lower Limbs - <https://esvs.org/wp-content/uploads/2023/03/ESVS-2022-CVD-Guidelines.pdf>
2. Rutherford's Vascular Surgery, 2-Volume Set, 8th Edition - 2014
3. Hamel-Desnos CM, Guías BJ, Desnos PR, Mesgard A. Foam sclerotherapy of the saphenous veins: randomised controlled trial with or without compression. *Eur J Vasc Endovasc Surg* 2010;39:500e7. - <https://esvs.org/wp-content/uploads/2023/03/ESVS-2022-CVD-Guidelines.pdf>
4. Michaels JA, Brazier JE, Campbell WB, MacIntyre JB, Palfreyman SJ, Ratcliffe J. Randomized clinical trial comparing surgery with conservative treatment for uncomplicated varicose veins. *Br J Surg* 2006;93:175e81 - <https://esvs.org/wp-content/uploads/2022/02/ToEs-Tables-of-Evidence-ESVS-2022-CVD-guidelines.pdf>
5. Cavezzi A, Mosti G, Colucci R, Quinzi V, Bastiani L, Urso SU. Compression with 23 mmHg or 35 mmHg stockings after saphenous catheter foam sclerotherapy and phlebectomy of varicose veins: a randomized controlled study. *Phlebology* 2019;34:98e106 <https://esvs.org/wp-content/uploads/2022/02/ToEs-Tables-of-Evidence-ESVS-2022-CVD-guidelines.pdf>

CONCLUSION

RFA of GSV has proved its self as a safe and effective method. More than 95% of patients are suitable for RFA during CVI in lower extremities, in others open surgical operations are indicated. The main complications rate was low, with the recanalization rate less than 4% and occlusion rate of 98.8 %. Also, hospital delay was minimal and return in normal function was in second day after procedure.

6. Wang H, Sun Z, Jiang W, Zhang Y, Li X, Wu Y. Postoperative prophylaxis of venous thromboembolism (VTE) in patients undergoing high ligation and stripping of the great saphenous vein (GSV). *Vasc Med* 2015, 20. Page 117,e21. - <https://esvs.org/wp-content/uploads/2023/03/ESVS-2022-CVD-Guidelines.pdf>
7. Van Rij AM, Chai J, Hill GB, Christie RA. Incidence of deep vein thrombosis after varicose vein surgery. *Br J Surg* 2004;91:1582e5 <https://esvs.org/wp-content/uploads/2022/05/ESVS-guidelines-extensive-version-18.05.2022.pdf>
8. Puggioni A, Marks N, Hingorani A, Shiferson A, Alhalbouni S, Ascher E. The safety of radiofrequency ablation of the great saphenous vein in patients with previous venous thrombosis. *J Vasc Surg* 2009;49:1248e55 - [https://www.ejves.com/article/S1078-5884\(15\)00097-0/fulltext](https://www.ejves.com/article/S1078-5884(15)00097-0/fulltext)
9. Lurie F, Kistner RL. Pretreatment elevated D-dimer levels without systemic inflammatory response are associated with thrombotic complications of thermal ablation of the great saphenous vein. *J Vasc Surg Venous Lymphat Disord* 2013;1:154e8 - [https://www.ejves.com/article/S1078-5884\(15\)00097-0/fulltext](https://www.ejves.com/article/S1078-5884(15)00097-0/fulltext)

დიდი საჩინო ვენის რადიოაბლაცია, უსაფრთხოება, ეფექტურობა, გართულებები

გიორგი ჯინჭველაძე, გურამ ვარდიშვილი, სანდრო წიქარიშვილი

კავკასიის მედიცინის ცენტრი, თბილისი

პასუხისმგებელი პირი: გიორგი ჯინჭველაძე, gioangio1@yahoo.com

DOI: <https://doi.org/10.48412/GTBGS.2024.12.61-64>

რეზიუმე მიზანი: დავადებით დიდი საჩინო ვენის რადიოაბლაციის პროცედურის უსაფრთხოება, ეფექტურობა, გართულებები ქვემო კიდურების ვარიკოზული დაავადების დროს.
 მეთოდი: პირველადი შეფასება დუპლექსონოგრაფიით, VCSS Score, CEAP კლასიფიკაციები, შეფასებულ იქნა 220 პაციენტი, 2017-2022 წლებში, რომლებსაც ჩაუტარდათ აღნიშნული ქირურგიული მკურნალობა.
 შედეგი: აღნიშნული 220 პაციენტიდან საშუალო ასაკი იყო 46.5 წ, სქესის შეფარდება, 170 (ქალი)×50 (კაცი). ოპერაციის შემდგომმა შეფასებებმა და დაკვირვებებმა აჩვენა წარმოდგენილი კლასიფიკაციების მიხედვით ძირეული გაუმჯობესება, როგორც დაავადების გამოსავალში ასევე ცხოვრების ხარისხში. ოკლუზიის სისშირე აღნიშნულ პროცედურებში იყო 98.8%, რეკანალიზაციის სისშირე 1 წლის შემდგომ 3.6%. ასევე ასაკი >65 წ, აღმოჩნდა რისკფაქტორი ისეთი პოსტოპერაციული გართულებების როგორცაა პიგმენტაცია, შეშუპება, პარესთეზია.
 დასკვნა: დიდი საჩინო ვენის რადიოაბლაცია არის უსაფრთხო და ეფექტური, ხასიათდება მინიმალური გართულებების რისკით, პოსტიტალიზაციის დროის სიმცირით და ცხოვრების ჩვეულ რიტმში სწრაფი დაბრუნებით. პაციენტების 95% მეტი ერგება ამ მეთოდით მკურნალობას, დანარჩენი 5% ღია ქირურგიულ მკურნალობას. ძირითადი გართულებები აღნიშნული პროცედურის დროს იყო დაბალი, რეკანალიზაციის სისშირე <4% და ოკლუზიის სისშირე 98.8%.

საკვანძო სიტყვები: დიდი საჩინო ვენის ენდოვენური აბლაცია, გართულებები, უსაფრთხოება, ეფექტურობა, გამოცდილება